

## Technical Note

# The Joint Jack: Report of a New Technique Essential for Elbow Arthroscopy

Ronald M. Selby, M.D., Stephen J. O'Brien, M.D., Anne M. Kelly, M.D., and Mark Drakos

---

**Abstract:** Visualization and access are of fundamental importance in arthroscopy, including arthroscopy of the elbow. A new technique not previously described in the literature improves both of these factors for key areas within the elbow that would otherwise be inaccessible. This technique employs the application of gentle leverage to pry apart the surfaces of the ulnohumeral articulation when viewing and working posteriorly to improve visualization and access to the ulnohumeral and radiocapitellar articular spaces. We believe this technique is essential for full arthroscopic viewing of the intra-articular regions of the ulnohumeral and radiocapitellar joints. **Key Words:** Arthroscopic—Elbow—Technique.

---

**E**lbow arthroscopy has become a commonly practiced technique over the past 15 years. Although not without risks, excellent visualization of intra-articular structures and access to intra-articular areas for problems such as loose bodies, adhesions, osteophytes, and synovitis are possible. The following is a description of a technique utilizing leverage to gain improved arthroscopic visualization and access for surgery within the ulnohumeral and radiocapitellar joints.

### TECHNIQUE

Arthroscopy of the anterior portion of the elbow is carried out first. Following satisfactory anesthesia (axillary block preferred) the patient is placed in the prone position, first described by Poehling et al.<sup>1,2</sup> The

arm to be operated on is placed in a well-padded holder near the shoulder that may accommodate a tourniquet if desired. The elbow is normally held at 90° of flexion.<sup>3</sup> The entire upper extremity is then scrubbed, prepped, and draped below the arm holder. Anatomic landmarks are then drawn including the medial and lateral epicondyles, tip of the olecranon, ulnar nerve, and radial head. A spinal needle is used with tubing and a syringe to insufflate the elbow joint carefully in the soft spot portal (also known as the direct lateral, midlateral, or transanconeus) in the triangle formed by the olecranon, radial head, and lateral humeral condyle. Joint distension and back flow ensure intra-articular positioning. The anterior portals are established with the joint fully distended and the elbow in 90° of flexion. A spinal needle is placed a thumb's breadth superior and anterior to the lateral epicondyle (proximal anterolateral portal<sup>4,5</sup>). Backflow confirms the intra-articular position of the spinal needle from this portal. A No. 11 blade is then used in the "nick-and-spread technique" to establish this proximal anterolateral portal. The arthroscope is introduced after the blunt trocar is placed with the side vent open, through which backflow again confirms the intra-articular positioning. Spinal needle localization is then used to establish the position for the anteromedial

---

*From the Sports Medicine and Shoulder Service, The Hospital for Special Surgery, Cornell University Medical Center; and St. Vincent's Hospital & Medical Center of New York, New York Medical College (R.M.S.), New York, New York, U.S.A.*

*Address correspondence and reprint requests to Ronald M. Selby, M.D., Orthopaedics & Sports Medicine, 20 West 13th St, New York, NY 10011-7902, U.S.A.*

© 2002 by the Arthroscopy Association of North America

0749-8063/02/1804-2870\$35.00/0

doi:10.1053/jars.2002.32239

portal (also known as proximal medial, approximately a thumb's breadth superior to the medial epicondyle and immediately anterior to the medial intermuscular septum<sup>1,6,7</sup>) under direct arthroscopic visualization. Backflow is checked with the spinal needle. The needle is then removed and a No. 11 blade is again used in the nick-and-spread technique. A pin is then placed to assure accurate positioning and a cannula is placed over the pin (Fig 1A) establishing the proximal medial portal. The cannula is left in place and the anterior portion of the elbow is evaluated and operated upon by moving the arthroscope and instruments alternately in these portals.<sup>5</sup>

While performing arthroscopy of the posterior elbow, the arthroscope is placed just medial to the mid-line in the direct posterior triceps-splitting portal after a spinal needle has assured intra-articular positioning. A tapered, blunt trocar (Fig 1B) is then placed via a portal just lateral to the lateral aspect of the triceps (posterolateral portal<sup>8</sup>) (Fig 2A). Spinal needle localization can prove valuable in the event that the anatomy or pathology dictates that an additional accessory portal be used. The cannulas are then introduced over tapered pins to further help assure accuracy and safety. The tapered, blunt trocar is placed at the posterior aspect of the ulnohumeral joint then slowly advanced, gently prying the articular surfaces apart (Fig 2B), thus gaining improved visibility and access to the ulnohumeral joint. The trocar is then used to lever open and thereby allow additional increased space for visualization of the ulnohumeral joint (Fig 2C). After inspection, the arthroscope is then slipped into the


ulnohumeral joint and is itself used to lever apart the articular surfaces (Fig 2D). The joint separation gives a unique opportunity to view the ulnohumeral articulation and radiocapitellar area, which are otherwise inaccessible to proper viewing and arthroscopic surgical treatment.

## ILLUSTRATIVE CASE EXAMPLES

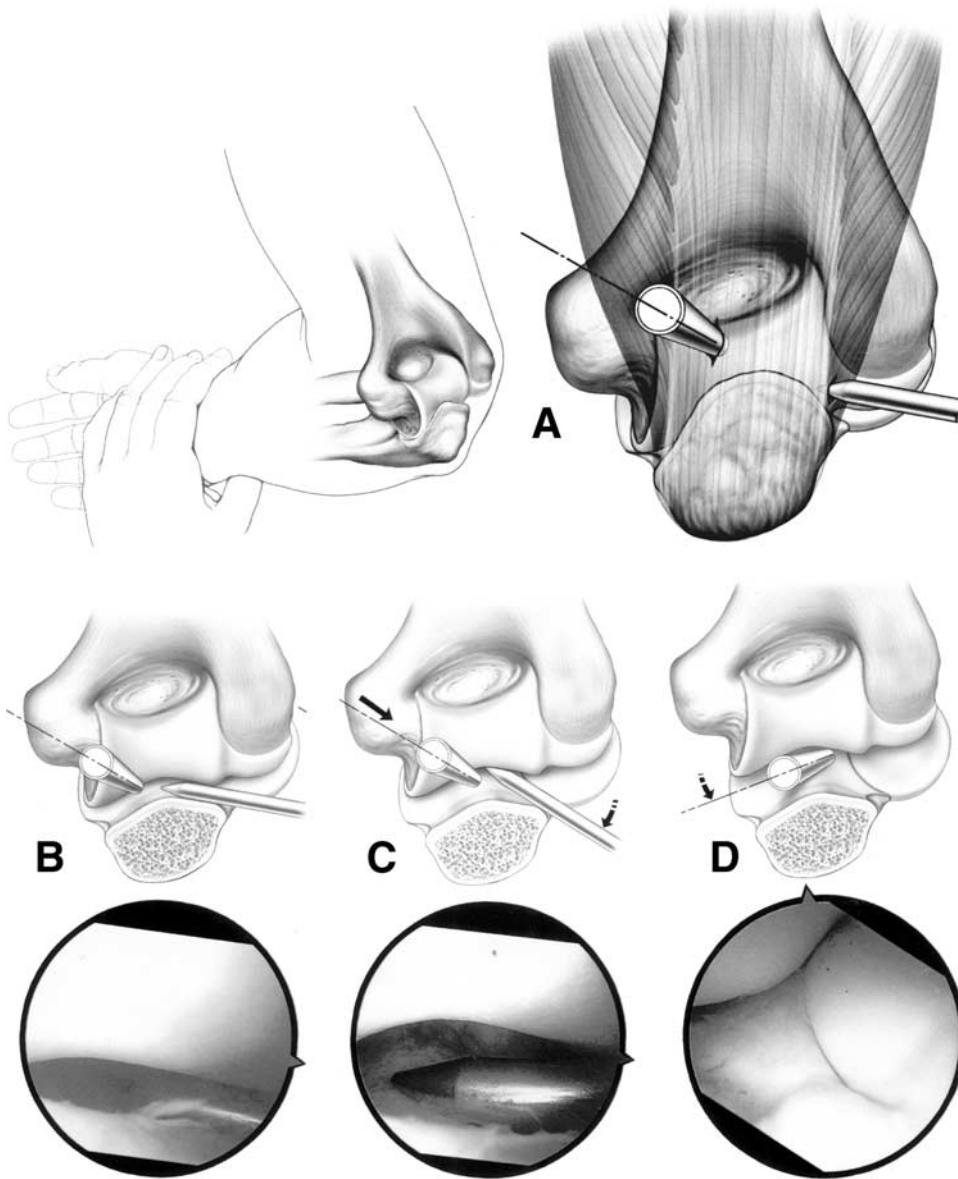
### Case 1

P.S. was a pleasant 39-year-old right-handed professional golfer who had experienced right elbow problems for about 1 year. He reported pain in the region of the radial head and deep inside the joint. The patient had a working diagnosis of lateral epicondylitis, which had not improved with injections or exercises. He did not have locking but the pain forced him to change his grip to a more pronated position, which affected his play. On physical examination, discrete tenderness was noted over the radial head. Pronation and supination in this area caused significant pain. The medial and lateral epicondyles were not tender. Resisted wrist extension did not cause pain. The patient did have pain with a parallel grip. No pain was noted with resisted flexion at the elbow. Round-the-clock radiographs (anteroposterior in extension, lateral at 90°, medial oblique in supinated extension, and lateral oblique in pronated extension) revealed a loose intra-articular body within the elbow, which was consistent with the clinical impression. Magnetic resonance imaging (MRI) showed a small loose body in the posterior recess of the elbow joint with cartilage irregularity of the posterior margin of the radial head. At arthroscopy, the anterior elbow joint appeared pristine. No abnormalities were seen from this view. The posterior joint was then entered through straight posterior and posterolateral portals as described.

Spinal needle localization assisted by fluoroscopy (Fig 3) helped determine the location of the loose body. The joint jack technique then afforded visualization of the ulnohumeral joint and ulnar side of the olecranon. On the lateral side of the ulnohumeral joint a large loose body was seen posteriorly wedged in between the olecranon and humerus. It was mainly attached to the distal humerus. The remainder of the joint was inspected, including the radial head, which was intact. A chondral defect in the ulna at the radio-ulnar joint was noted and felt to be the source of the loose body, which then wedged posteriorly between



**FIGURE 1.** (A) Modified Steinman pin (5/64-inch) (Richards, Memphis, TN), trocar (modified) (Accuflex, Mansfield, MA), and an Accuflex 5.0-mm cannula (shown above assembled on trocar and Steinman pin). (B) Although a specific instrument may be developed, in the past we have used a tapered, blunt trocar (Dyonics, Andover, MA).

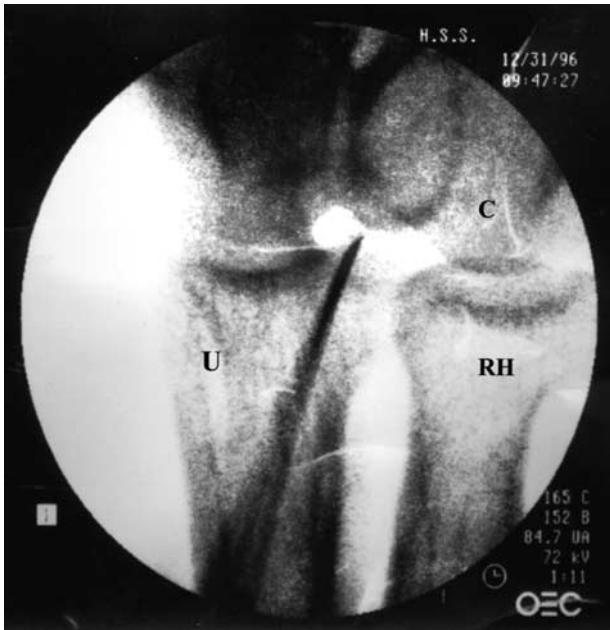

**FIGURE 2.** (A) An overview of the right elbow with the patient in the prone position with an arthroscope entering the posterior portal and a tapered, blunt trocar entering the "soft-spot portal." (B) Trocar at posterior ulnohumeral joint. The blown-up view shows the corresponding arthroscopic intra-articular view with the tip of the trocar prying open the ulnohumeral joint. (C) Leverage achieved by trocar via joint jack technique. (D) View obtained by joint jack with advancement and levering of arthroscope.

the humerus and the ulna. The chondromalacic donor region was debrided gently and the posterior aspect of the ulnohumeral articulation was then entered via an additional portal. A probe was used to free the loose body from where it had been wedged into the distal humerus. Once freed, the loose body was then removed with the grasper. An arthroscopic shaver was used to gently debride the irregular bed that had been housing the loose body. Free motion of the joint was obtained at this point. Fluoroscopy was used to check the joint and to assure that the loose body, previously evident on radiography as well as fluoroscopy, had been removed.

## Case 2

J.R. was a 23-year-old woman who had sustained an elbow fracture and possible dislocation 2 years before presentation. She was treated conservatively and was doing extremely well and was asymptomatic until 1 week prior to presentation when she felt something getting stuck in her elbow. She reported limited motion overnight. When she awoke the next day the motion was restored but she continued to experience discomfort. On physical examination, medial collateral ligament laxity was found with a mild increase in valgus as compared to the contralateral "normal" el-



**FIGURE 3.** Intraoperative fluoroscopy showing spinal needle localization of a loose body at its tip, with the radiocapitellar joint on the right, ulnohumeral joint to the left. RH, radial head; C, capitellum; U, ulna.

bow. Full flexion, extension, supination, and pronation were noted. Some tenderness was noted over the area of the radial head. The remainder of the elbow was not tender.

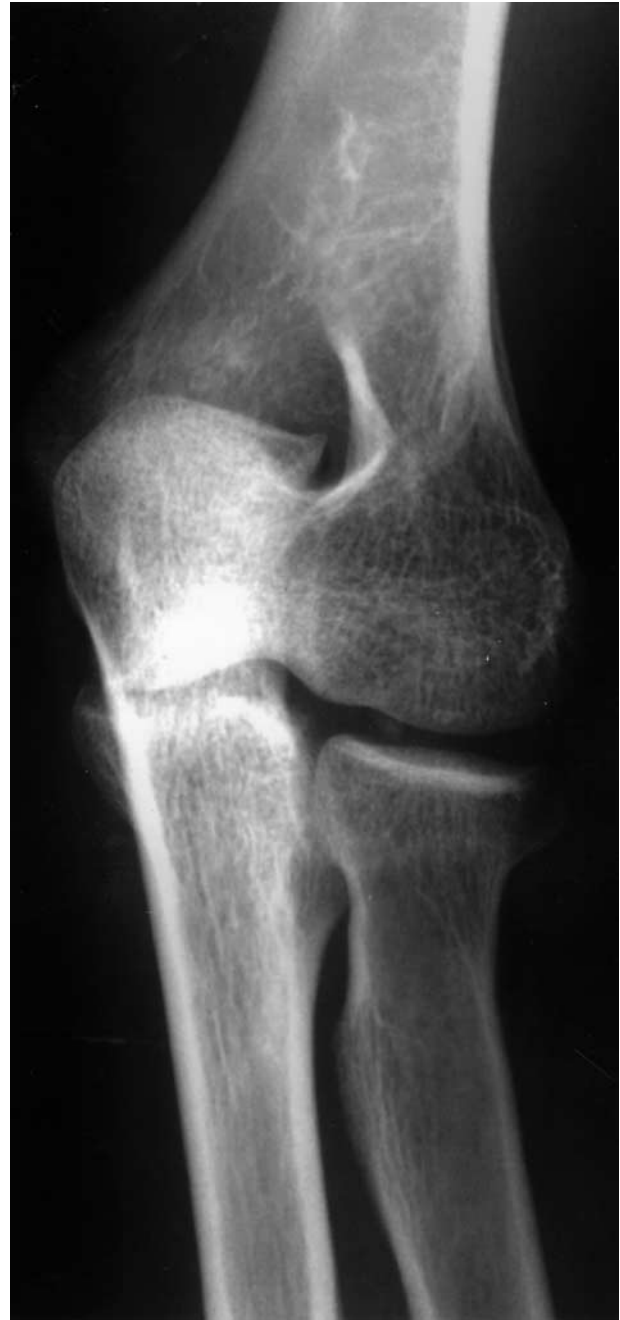With a working diagnosis of a post-traumatic loose body and a history suggestive of a locking episode, radiographs and an MRI were obtained. Round-the-clock radiographic views revealed an osseous density proximal to the radial head most consistent with an intra-articular loose body (Fig 4). It could not be identified on the lateral view. No evidence of a joint effusion was noted. The MRI did not show an intra-articular body. Mild cartilage wear at the radiocapitellar joint and an irregularity of bone at the medial trochlea with a small osteophyte was seen.

Arthroscopy was performed for debridement and removal of the loose body. Mild anterior scarring noted on arthroscopic evaluation was resected. The anterior chondral surfaces were found to be intact and no loose bodies could be seen. Significant scarring was seen posteriorly and this was also resected. The joint jack approach was then used to evaluate the ulnohumeral groove and the bare spot. Using this technique, a loose body was found wedged in the radiocapitellar recess (see Fig 5). This was then easily removed, as was lateral scar tissue. The cartilage

surfaces were otherwise intact (Fig 6 shows the elbow after removal of the loose body).

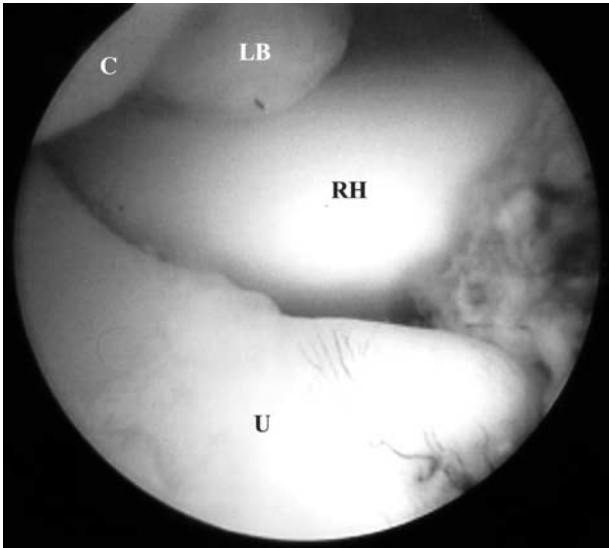
### Case 3

L.R. was a 51-year-old male tennis player presenting with increasingly restrictive motion, pain, and



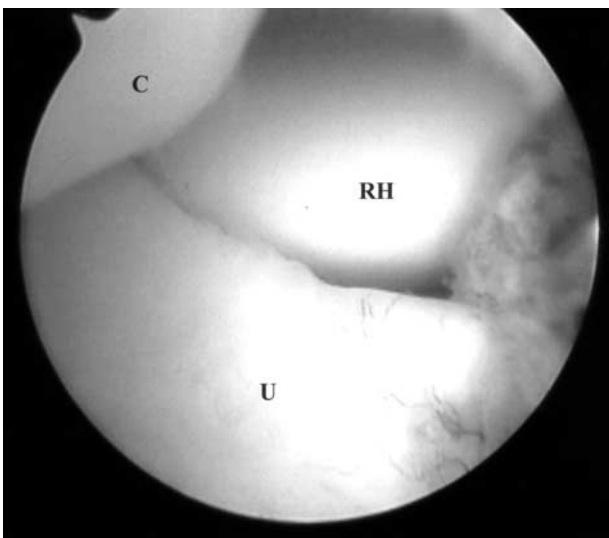
**FIGURE 4.** Radiograph of the right elbow from a round-the-clock series showing an intra-articular loose body (between radial head and capitellum).



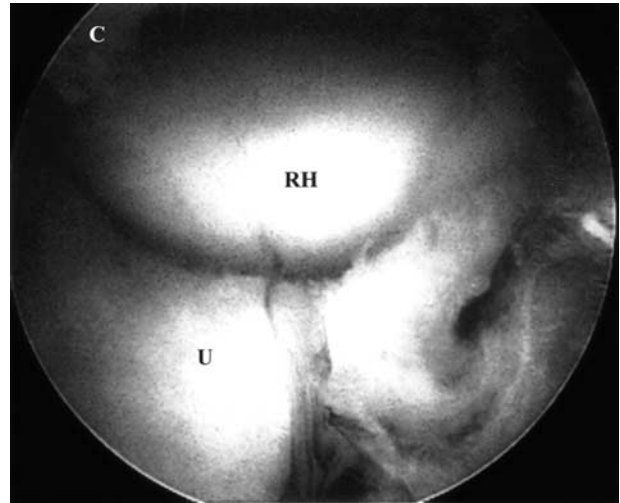


**FIGURE 5.** With the patient in the prone position, the arthroscope is through the posterior portal of the right elbow and into the ulnohumeral articulation, levering it open. The loose body (LB) is shown wedged between the capitellum (C) and radial head (RH). The bare area of the ulna (U) is seen in the foreground.

aching of his right elbow for 3 to 4 years. On physical examination, the patient lacked approximately  $10^{\circ}$  of extension and approximately  $10^{\circ}$  of flexion. Supination and pronation were painful. The patient was sore with resisted extension. No tenderness over the medial collateral ligament and no medial or lateral instability were noted. Radiographs showed posterior spurring suggestive of degenerative changes in the capitellum



**FIGURE 6.** Same view as Fig 5 after removal of loose body.



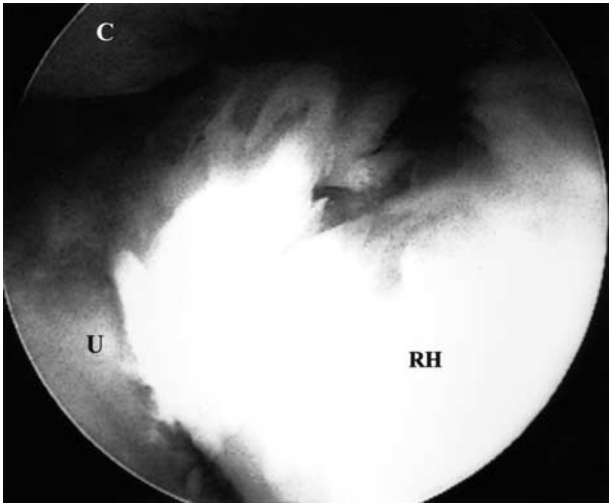
**FIGURE 7.** The patient is in the prone position with the arthroscope entering the posterior portal of the right elbow and levering open the ulnohumeral articulation with this view of the radiocapitellar joint.

and moderate degenerative joint disease. With a diagnosis of degenerative joint disease and loose bodies of the right elbow, arthroscopy was undertaken for debridement and removal of loose bodies.

Arthroscopy was carried out with the patient in the prone position. After the anterior elbow had been evaluated, the arthroscope was placed posteriorly following spinal needle localization. At first, the ulnohumeral and radiocapitellar joints appeared unremarkable (Fig 7). While viewing the radiocapitellar area with the arthroscope in the direct posterior portal and levered into the ulnohumeral articulation, the forearm was supinated and a loose body was revealed (Fig 8). Use of the joint jack technique afforded a circumferential view of the radial head. The initial arthroscopic visualization of the radial head showed no pathology. Then the same view after supination demonstrated the pathology and allowed access to perform the surgery.

## DISCUSSION

This technique has been used on virtually all elbow arthroscopies performed by the senior author (S.J.O.) for the past 5 years. The joint separation gives a unique view of the radiocapitellum joint and ulnohumeral joint, which otherwise remain obscure and inaccessible. It affords access to areas not seen with standard arthroscopic techniques within the elbow and changes the perception of "looking at" the articulations to "looking into" the articulations. Of particular



**FIGURE 8.** This is the same setup as in Fig 7 but shows how the pathology came into view with supination of the forearm.

note is the ulnar aspect of the radiocapitellar joint, a common site for loose bodies. When present, spinal needle localization will allow accurate portal placement for instruments used for their removal. For these

reasons we propose that this technique should be an essential part of every elbow arthroscopy for *complete* visualization. Because of the success we have had with this technique we have also begun applying it to other joints, most notably the ankle.

## REFERENCES

1. Poehling GG, Whipple TL, Sisco L, Goldman B. Elbow arthroscopy: A new technique. *Arthroscopy* 1989;5:222-224.
2. Ekman EF, Poehling GG. Arthroscopy of the elbow. *Hand Clin* 1994;10:453-460.
3. Carson WG Jr. Arthroscopy of the elbow. *Instr Course Lect* 1988;37:195-201.
4. Field LD, Altchek DW, Warren RF, O'Brien SJ, Skyhar MJ, Wickiewicz TL. Arthroscopic anatomy of the lateral elbow: A comparison of three portals. *Arthroscopy* 1994;10:602-607.
5. Slothers S, Day B, Regan WR. Arthroscopy of the elbow: Anatomy, portal sites, and a description of the proximal lateral portal. *Arthroscopy* 1995;11:449-457.
6. Lindenfeld TN. Medial approach in elbow arthroscopy. *Am J Sports Med* 1990;18:413-417.
7. Baker CL Jr. Normal arthroscopic anatomy of the elbow: Surgical technique with the patient prone. In: McGinty JR, ed. *Operative arthroscopy*. Ed 2. New York: Lippincott-Raven, 1996;869-876.
8. O'Driscoll SW, Morrey BF. Arthroscopy of the elbow. In: Morrey BF, ed. *The elbow and its disorders*. Ed 2. Philadelphia: WB Saunders, 1993;120-130.